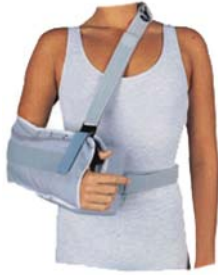

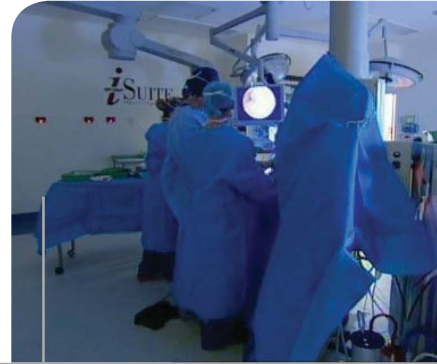Post Operative Care

A sling with a small pillow for six weeks, during which time simple passive range of motion is initiated, driving a car after 1 week.

At six weeks a more active range of motion is initiated. Return to overhead activities usually occurs at between 3 and 4 months.



George Murrell
Shoulders




PROF GEORGE MURRELL
The Church
17 Kensington St
Kogarah, 2217
Sydney, Australia

1. Bryant L, Shnier R, Bryant C, Murrell GAC: A comparison of clinical estimation, ultrasonography, magnetic resonance imaging, and arthroscopy in determining the size of rotator cuff tears. *J Shoulder Elbow Surg* 11:219-24, 2002
2. Millar NL, Tantau R, Silverstone E, Wu X, Murrell GAC: Open versus two forms of arthroscopic rotator cuff repair: a prospective analysis of repair integrity and clinical outcomes in 153 patients. *10th International Congress of Shoulder and Elbow Surgery, Brazil, 2007.*
3. Murrell GAC, Walton J: Diagnosis of rotator cuff tears. *Lancet* 357:769-70, 2001
4. Paoloni JA, Appleyard RC, Nelson J, Murrell GAC: Topical glyceryl trinitrate application in the treatment of chronic supraspinatus tendinopathy: a randomized, double-blinded, placebo-controlled clinical trial. *Am J Sports Med* 33: 806-13, 2005
5. Yamaguchi K, Tetro AM, Blam O, Evanoff BA, Teeffey SA, Middleton WD: Natural history of asymptomatic rotator cuff tears: A longitudinal analysis of asymptomatic tears detected sonographically. *Journal of Shoulder and Elbow Surgery* 10:199-203, 2001

PROF GEORGE MURRELL

ROTATOR CUFF TEARS



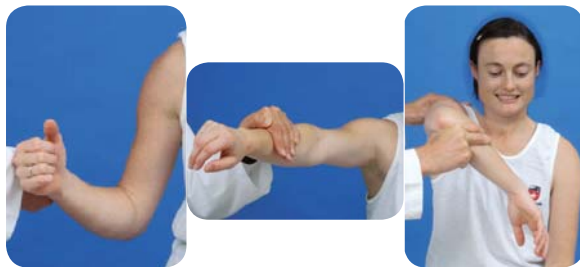ROTATOR CUFF TEARS

The rotator cuff consists of four tendons that surround the humeral head and seat it against the glenoid. When working well, the rotator cuff allows the arm to function overhead.

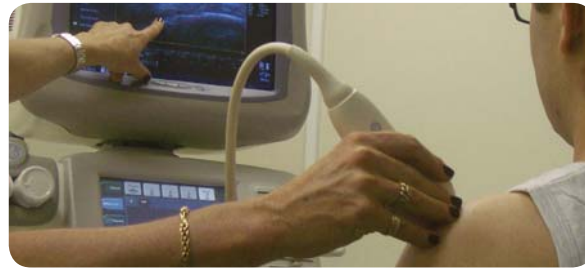When not working patients classically present with pain with overhead activities and pain at night.

Diagnosis

The three most useful clinical tests are: weakness on external rotation, weakness on supraspinatus testing and a positive impingement sign³. Rotator cuff tears can be ruled in or ruled out using these tests:



Clinical Tests Positive	Age	Chance of Rotator Cuff Tear
All 3	Any	98%
Any 2	>60	98%
None	Any	5%



Imaging

We have found our ultrasound service to be a fast, accurate and non-invasive way of confirming the diagnosis¹. Xrays are important for ruling out other pathology.

Management

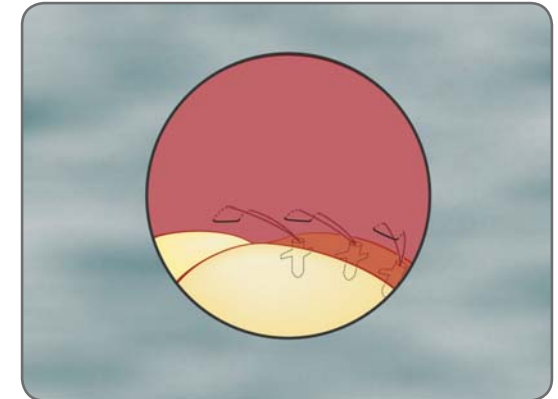
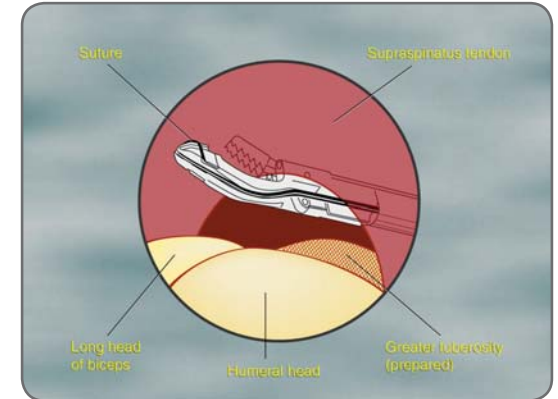
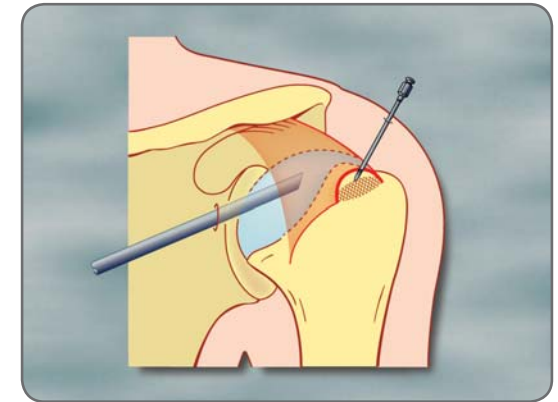
Partial-thickness tears are initially treated as per impingement with a corticosteroid injection in the subacromial space, followed by rehabilitation. If these fail, arthroscopic acromioplasty.

Full-thickness tears enlarge with time⁵, and I recommend early surgical repair.

Arthroscopic Repair

Technological advances are making it easier and easier to repair rotator cuffs as half day cases under regional anaesthesia.

The tear is repaired through keyholes using sutures and suture anchors (small metal anchors that go into bone and stay there permanently).



In our hands the newer techniques² give better:

- Pain relief
- Range of motion
- Repair integrity